ELSEVIER

Early Human Development 67 (2002) 19–28

Early Human Development

www.elsevier.com/locate/earlhumdev

Immunological detection of 4-hydroxynonenal protein adducts in developing pontine and Purkinje neurons and in karyorrhexis in pontosubicular neuronal necrosis

Atsuo Itakura [a,*], Osamu Kurauchi [b], Sachio Takashima [c], Koji Uchida [d], Mitsuaki Ito [a], Shigehiko Mizutani [a]

[a] *Department of Obstetrics and Gynecology, Nagoya University School of Medicine, 65 Tsurumai-cho, Showa, Nagoya 466-8550, Japan*

[b] *Department of Obstetrics and Gynecology, Nagoya Dai-ni Red Cross Hospital, Nagoya, Japan*

[c] *Department of Clinical Laboratory, National Center Hospital for Mental, Nervous and Muscular Disease, National Center of Neurology and Psychiatry, Kodaira, Tokyo, Japan*

[d] *Laboratory of Food and Biodynamics, Nagoya University School of Agriculture, Nagoya, Japan*

Received 9 March 2001; received in revised form 15 August 2001; accepted 1 November 2001

Abstract

Four-hydroxynonenal (HNE) has been proposed as an important marker of radical-induced lipid peroxidation. The principal objective of this study was to assess the occurrence of lipid peroxidation in normal perinatal brain and brains with one form of pontosubicular neuronal necrosis (PSN). Immunochemical studies using an antibody against HNE-modified protein were performed in controls aged from 20 weeks of gestation to 64 years, and patients with PSN. Immunohistochemical study showed developmental and aging changes of positive staining in Purkinje cells and pontine neurons (27 weeks–7 months, 50 and 64 years). In addition, karyorrhectic cells in pontine nuclei with PSN were positively stained. Immunoblotting revealed that a 75-kDa protein, which is speculated to be mitochondrial complex-1 protein, was the most intensely expressed among multiple immunoreactive proteins. Our results identified the presence of oxidative stress in the perinatal neuron, and this oxidative stress may contribute to some forms of karyorrhectic death. © 2002 Elsevier Science Ireland Ltd. All rights reserved.

Keywords: 4-Hydroxynonenal; Pontosubicular neuronal necrosis

* Corresponding author. Tel.: +81-52-744-2261; fax: +81-52-744-2268.
E-mail address: aita@med.nagoya-u.ac.jp (A. Itakura).

0378-3782/02/$ - see front matter © 2002 Elsevier Science Ireland Ltd. All rights reserved.
PII: S0378-3782(01)00247-X

PM3006739444

Source: https://www.industrydocuments.ucsf.edu/docs/srnx0001

1. Introduction

Fetal brain damage, which often is associated with cerebral palsy, is well known to derive from the processes causing hypoxia–ischemia to the fetus. In addition to the ischemia-related cell injury a hypoxia episode may also leads to the delayed cell damage, which appears selectively in some organs such as brain, liver, and cardiac tissue. Neurons of the brain are sensitive to both transient anoxic injury and to the oxidative stress of reduced oxygen supply, which generates lipid peroxides contributing to the disruption of neurons [1,2]. Since the antioxidant enzymes are immature in fetal brain, both enrichment of polyunsaturated fatty acids and lipid peroxidation occurs easily in not only preterm, but also full term neonates [3,4]. Therefore an important mechanism suspected for hypoxic–ischemic damage in the brain of premature neonates is possibly due to the increased production of oxidant species [5].

Four-hydroxynonenal (HNE) is an α, β-unsaturated aldehyde that is produced from the oxidation of membrane lipid polyunsaturated fatty acids. HNE easily reacts with various biological materials and form stable adducts, and it interferes the functions of biological substances. Therefore, HNE is considered to be cytotoxic under oxidative stress and to be the most reliable index of lipid peroxidation. In previous reports, we have described the preparation of polyclonal antibodies against HNE-modified proteins, which recognizes HNE-protein epitopes. It was used to detect HNE-protein adducts in tissue slices including nigral cells in Parkinson disease and trophoblast in preeclampsia [6–8].

Pontosubicular neuronal necrosis (PSN) is a distinct type of perinatal pathological brain lesion, which is characterized by neuronal karyorrhexis in the pontine nuclei and the subiculum [9,10]. However, karyorrhexis is also noted in a more diffuse distribution, involving the Purkinje cell layer, lateral geniculate body, inferior olivary nucleus, and thalamus [11]. PSN is a brain lesion predominantly affecting premature infants and is most likely caused by a combination of anoxia, hypercapnia and hypoglycemia [12,13]. Tan et al. [14] demonstrated that sustained hypoxia–ischemia increases nuclear karyorrhexis in the premature fetal rabbit brain.

In this study, we investigated the expression of HNE protein adducts in human fetal and adult brain tissue by immunochemical method and discussed the possible involvement of HNE in PSN.

2. Materials and methods

2.1. Clinical subjects

From a review of autopsy brain bank at the National Institute of Neuroscience, we selected 23 adults, infants, and still birth fetuses with normal neuropathological finding except for mild subarachnoidal hemorrhage or brain edema as a normal group, and 20 neonates and still birth fetuses as PSN group whose gestational ages ranged from 24 to 41 weeks of gestation (GW).

Neuropathological reports of macroscopic examination were reviewed and sections of frontal lobe, occipital lobe, cerebellum, mid brain, pons, and basal ganglia were evaluated microscopically.

PM3006739445

Source: https://www.industrydocuments.ucsf.edu/docs/srnx0001

For positive control in Western blotting a preeclamptic placenta was used, in which the expression of HNE-modified protein has been confirmed by immunohistochemistry in a previous study [6].

The study was approved by the Institutional Ethic Committee at Nagoya University School of Medicine.

2.2. Immunohistochemistry

Brain tissues were fixed 10% formalin for 2–3 weeks, then embedded in paraffin, and were cut in 4-μm sections. Sections were deparaffinized by xylene and ethanol. Endogenous peroxidase activity was quenched by 3% H_2O_2 for 15 min at room temperature. The primary antibody was the HNE-protein adduct antiserum described above diluted by 10% normal goat serum. The sections were incubated with the primary antibody overnight at 4 °C. After three washes in PBS, the sections were incubated for 30 min at room temperature with biotin labeled anti-rabbit IgG. After three washes in PBS, the sections were incubated for 10 min at room temperature with peroxidase-labeled streptoavidin and washed three times (Vectastain, Vector, Burlingame, CA). The immunoreaction was visualized using diaminobenzidine as the chromogenic substrate and counterstained with hematoxylin.

Analysis by light microscopy was conducted by two neuropathologists. HNE-modified protein positive cells were classified into four groups of neurons: (−), not stained; (±), exceptional cells stained; (+), few cells stained; and (++), many cells stained.

2.3. Western blotting

Western blot analysis was performed by a standard method [15]. Specimens from the pons were obtained post mortem from a patient with PSN as well as two normal control subjects. Pons samples were washed in saline, frozen immediately in liquid nitrogen, and stored at −80 °C until use. Mitochondrial fraction of preeclamptic placenta tissue were prepared described previously [6]. In brief, fresh placental tissue was obtained from the delivery of a 34 weeks infant with severe preeclampsia (systolic blood pressure above 180 mm Hg together with general edema and proteinuria). Placental homogenate in 0.25 M sucrose, 3 mM Tris–HCl (pH 7.4), 0.1 mM EDTA was centrifuged at 700 × g for 10 min. The supernatant was centrifuged at 5000 × g for 10 min. The pellet was resuspended and centrifuged as above. The resulting pellet was used as the mitochondrial fraction. For the extraction of proteins, samples were thawed and homogenized in a 2% SDS loading buffer. After centrifugation, supernatants were collected, and protein assay was performed using the method of Bradford. Western blot analysis for the prepared sample (60 μg/lane) was performed by electrophoretic transfer to nitrocellulose sheets (Hybond-C Super, Amersham, England) after SDS/PAGE using a 10% polyacrylamide gel. After electrophoresis, proteins were electrotransfered to polyvinilidene-difluoride membrane (PVDF) (Bio-Rad Labs, Hercules, CA) with Bio-Rad Mini Trans-Blot apparatus. Nonspecific reactivity on the PVDF membranes was blocked with nonfat dry milk. After washing, the PVDF membranes were incubated with polyclonal antibody against HNE-protein adduct. Immu-

PM3006739446

Source: https://www.industrydocuments.ucsf.edu/docs/srnx0001



Fig. 1. Immunohistochemistry using anti HNE-protein polyclonal antibody was performed onbrains with PSN in infants due to neonatal asphyxia. Photomicrographs of the section of human pons, (a, b), hemisphere of cerebellum (c), and cerebral cortex (d). The reactivity was observed in the cytoplasma of pontine nulcei (a), karyorrhectic neurons (b Arrow) of pons and Purkinje cells in hemisphere of cerebellum (c). However, no reactivity was detected in cerebral cortex (d) as well as other region (data not shown). E is negative control of Pons in which incubated with non-immune rabbit IgG instead of primary antibody. Scale Bar: (a, c, e) 20 μm; (b) 100 μm; (d) 40 μm.

PM3006739447

Source: https://www.industrydocuments.ucsf.edu/docs/srnx0001

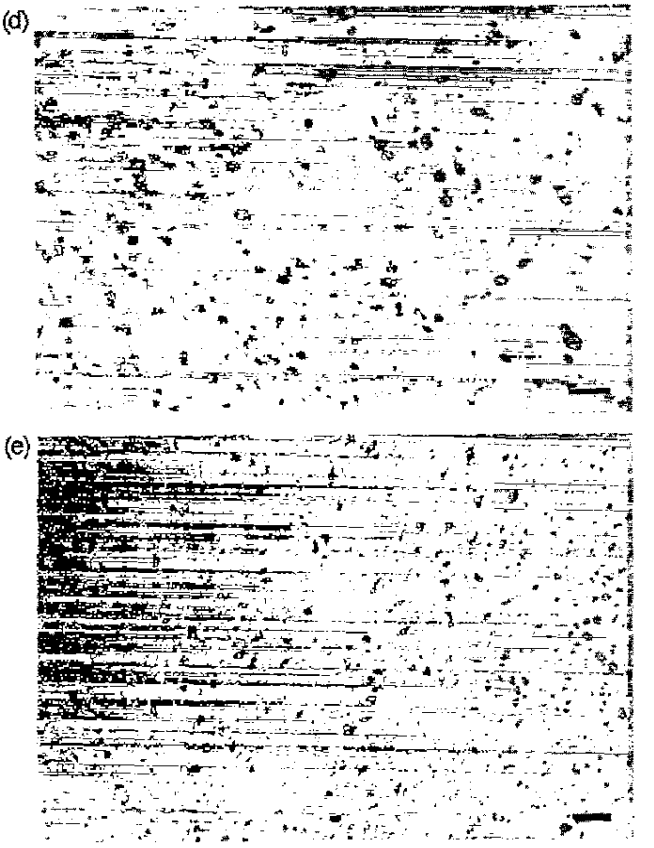

Fig. 1 (*continued*).

noreactive proteins were stained using a chemiluminescence system (ECL, Amersham International, Buckinghamshire, England).

3. Results

3.1. Immunohistochemistry

Fig. 1 shows typical immunolocalization of HNE-modified proteins in a subject with PSN who died at the second day of birth due to neonatal asphyxia. The immunoreactivity was observed in the cytoplasma of neurons in pontine nulcei (Fig. 1a), tegmentum, and karyorrhectic neuron (Fig. 1b) of pons. Purkinje cells and their dendrites in the cortex of cerebellar hemisphere were also clearly stained (Fig. 1c). However, no immunoreactivity was detected in glial cells and cerebral cortical neurons (Fig. 1d). Similarly, we underwent

PM3006739448

Source: https://www.industrydocuments.ucsf.edu/docs/srnx0001

immunohistochemical evaluation for the pons and cerebellum of 20 PSN subjects and 23 normal subjects.

In the cerebellum of normal controls, the immunoreactivity appeared from 27 GW to 7 months of age, and reappeared 50 and 64 years (Table 1). In the pons, there was the same tendency as the cerebellum, although the first appearance of positivity was at 23 GW in the tegmentum and at 33 GW in the basis of the pons. On the other hand, similar reactivities were observed in the pons and cerebellum of PSN subjects as shown in Table 2. Except for very premature infants, Purkinje cells in the cerebellum and neurons in the pontine nuclei and tegmentum of the pons showed the positive reactivity (±, +, ++). The staining pattern was similar in the pons and cerebellum from normal subjects and from PSN subjects. Furthermore, in 15 of 20 cases, the immunoreactivity of HNE-modified protein was also observed in pontine karyorrhectic neurons. Karyorrhectic neurons were negative from the subjects at <27 GW and after 13 days of age.

3.2. Western blotting

Fig. 2 depicts Western blot analysis of HNE-modified proteins in human pons homogenates and the preeclamptic placental mitochondrial fraction. Except for the case

Table 1
HNE-protein expression in the infants without neuropathological findings

No.	Age	Cerebellum	Pons	
		Purkinje cells	Pontine nuclei	Tegmentum
1	20 weeks	−	−	−
2	21 weeks	−	−	−
3	22 weeks	−	−	−
4	23 weeks	−	−	±
5	27 weeks	+	−	±
6	27 weeks	±	−	+
7	33 weeks	±	+	+
8	33 weeks	+	±	±
9	34 weeks	++	+	+
10	35 weeks	+	+	±
11	37 weeks	±	+	±
12	39 weeks	++	+	±
13	40 weeks	+	+	+
14	1 months	+	++	+
15	3 months	+	+	±
16	7 months	++	++	±
17	1 year and 4 months	−	−	−
18	1 year and 7 months	−	−	−
19	2 years	−	−	−
20	11 years	−	−	−
21	18 years	−	−	−
22	50 years	+	++	±
23	64 years	+	+	+

Scores represent subjective assesments of numbers of stained cells as follows: −: no staining observed; ±: exceptional cells stained; +: few cells stained; ++: many cells stained; ND: not done.

PM3006739449

Source: https://www.industrydocuments.ucsf.edu/docs/srnx0001

Table 2
HNE-protein expression in the infants with PSN

No.	Age (week)	Age at death (days)	Cerebellum		Pons	
			Purkinje cells	Pontine nuclei	Tegmentum	Karyorrhectic neuron
1	24	7	−	−	−	−
2	24	30	−	−	−	−
3	26	13	±	−	−	−
4	27	42	±	±	+	+
5	29	2	+	±	+	±
6	32	1	+	+	+	++
7	32	3	+	±	++	±
8	35	1	+	+	±	+
9	36	0	++	±	+	+
10	36	Still birth	+	+	+	±
11	38	0	++	+	+	±
12	38	2	++	±	+	+
13	38	10	+	+	+	+
14	38	18	++	++	++	−
15	39	1	+	+	+	±
16	40	1	++	+	+	++
17	40	2	+	±	+	−
18	40	2	++	+	++	±
19	41	2	+	+	±	+
20	41	Still birth	++	±	±	++

Scores represent subjective assesments of numbers of stained cells as follows: −: no staining observed; ±: exceptional cells stained; +: few cells stained; ++: many cells stained; ND: not done.

at 18 GW, multiple bands were detected, and these bands were more intensely stained in the homogenates with PSN, although no apparently differences in molecular weight of the bands was observed among each pons homogenate. The most intensely stained band at approximately 75-kDa corresponded to the single band recognized in the placental mitochondrial fraction obtained from preeclamptic patient.

4. Discussion

Our data showed that HNE-modified protein is normally expressed in neurons of the pons and cerebellum and it is also in the karyorrhectic neurons of infantile brains with PSN. Most normal pontine nuclei and Purkinje cells during perinatal and early infantile periods showed positive staining for HNE-modified proteins, suggesting that oxidative stress might be ubiquitous at these sited during these periods. It is possible that the presence of lipid peroxidation in normal neurons of the pons and cerebellum contribute oxidative stress to neurons which develops karyorrhexis in fetuses and neonates (Tables 1 and 2).

The fetal brain is enriched with arachidonic acid and docosahexaenoic acid, both of which increase toward birth. It has a lower activity of cellular antioxidant and free radical scavengers. Therefore, some degree of hypoxia, possibly induced by the physiological stress of birth, may result in a significant increase of lipid peroxidation, with a concomitant

PM3006739450

Source: https://www.industrydocuments.ucsf.edu/docs/srnx0001

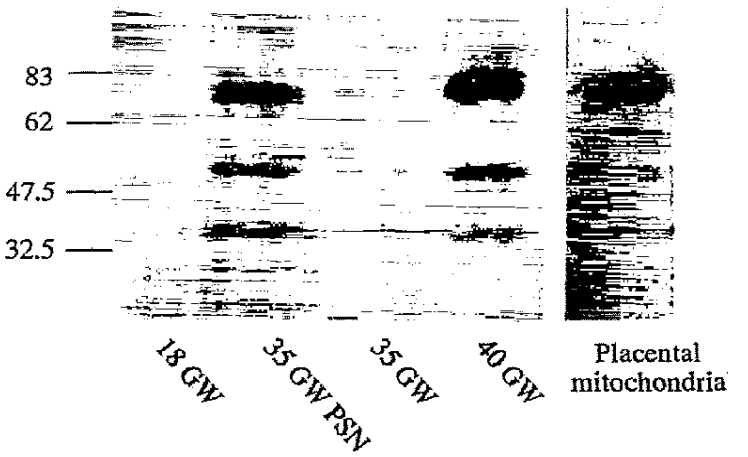

Fig. 2. Immunoblot analysis using HNE-protein of brain homogenates from the patients without PSN (18 GW), with PSN (35 GW), without PSN (35 GW), without PSN (40 GW), and placental mitochondrial fraction with preeclampsia. The samples were prepared as described in Materials and Methods. Numbers refer to the molecular weight standards ($\times 10^{-3}$).

decrease in total antioxidant. Such lipid peroxidation has been described to occur in brain of human healthy neonates [4]. Further investigations are necessary to determine whether HNE-modified protein is expressed in physiological conditions or not; however, our study confirms that HNE-modified protein is readily increased within pontine nuclei and cerebellum during perinatal and early infantile periods.

Under reoxygenation following hypoxia, polyunsaturated fatty acids may exacerbate cellular damage in the premature brain. Or, a second stress or dying may induce HNE-modified protein. Our immunochemical studies using perinatal clinical subjects inevitably suffer from a lack of comparison with true normal matched control subjects.

The etiology of PSN and the pathogenesis of karyorrhexis have not been completely elucidated; acute ischemia is considered to be an important underlying pathogenic factor. Fetal sustained hypoxic–ischemic stress induces both increased oxygen free-radical production and generation of lipid peroxides and results in an increased hippocampal nuclear karyorrhexis compared with controls [3,14]. In addition, oxidative stress is one of the most important inducing factors of apoptosis, whereas ischemia-induced neuronal cell death has been primarily attributed to necrotic processes. Therefore, oxidative stress after acute ischemia may be associated with the occurrence of karyorrhexis in PSN. It has been shown that copper, zinc-superoxide dismutase (Cu Zn-SOD), which is an antioxidant enzyme involved in primary defense against free radical damages, is present in neonatal neurons of pons and cerebellum, and not cerebrum in brains with PSN at earlier stage of fetal brain injury [16]. The positive regions of Cu Zn-SOD at an early stage are those with HNE-modified protein. Interestingly, the immunoreactivity of superoxide dismutase was negative in the karyorrhectic neurons. Accordingly, karyorrhectic cell death with PSN may be considered as a result from oxidative stress without the induction of antioxidant defense system.

PM3006739451

Source: https://www.industrydocuments.ucsf.edu/docs/srnx0001

In this study, 5 of 20 clinical subjects from patients with PSN did not express HNE-modified protein. A possible explanation of these negative results is that some karyorrhexis also occurs without oxidative stress. We have discovered that the karyorrhexis is more widely distributed than those reported previously [11]. And our present results are consistent with the hypothesis that karyorrhexis may occur physiologically in the process of neuronal maturation besides resulting from acute ischemia.

Our Western blotting data clearly showed that fetal brain homogenates with or without PSN have a few proteins bound to HNE. Among them the 75-kDa band of immunoblotting was the strongest immunoreactive protein. Previously we reported that a mitochondrial protein apparently corresponding to the iron–sulfur protein of complex I (NADH) were expressed at the size of 75-kDa by the antibody against HNE-modified protein in preeclamptic placenta [6]. There is evidence that mitochondrial function and glutamate transport are compromised in neurodegenerative conditions that involve oxidative stress [17,18]. Indeed, Keller et al. [19] described that HNE binds and impairs glutamate transporter-1 (GLT-1) of synaptosomes, which express a broad band with maximum density at around 73-kDa on immunoblots. However, the regional localization of GLT-1 is restricted to astroglia [20,21], and the immunohistochemistry in this study shows that HNE-modified protein localizes to pontine neurons. Therefore, the strongest immunoreactive 75-kDa protein is interpreted to be components of mitochondrial complex I.

HNE is considered to be one of the most reliable markers of lipid peroxidation. Recently HNE antibody has been used to detect free-radical involvement in Parkinson disease [22], familial amyloidotic polyneuropathy [23], Alzheimer's disease [24], and spinocerebeller degeneration [25]. As in this study, Purkinje cells in olivopontocerebeller atrophy patients were immunostained with HNE antibody, whereas the other neurons and glia cells in the cerebellum were not positively stained. These results suggested a significant increase in lipid peroxidation in Purkinje cells in olivopontocerebeller atrophy patients, and increased lipid peroxidation seemed to contribute to the degeneration of Purkinje cells in olivopontocerebeller atrophy. However, further investigation will be needed to clarify the significance of lipid peroxidation in Purkinje cells, which we have observed during perinatal and early infantile periods.

In conclusion, we have confirmed that lipid peroxidation increases in the perinatal brain without any apparent neuropathological findings, but that it may be involved in the process of neuronal karyorrhexis in PSN.

Acknowledgements

This work is supported in part by a Grant-in-Aid (11671608) to A.I. from the Ministry of Education, Science, and Culture of Japan and a Grant from Ogyaa donation.

References

[1] Adams JA. Hypoxic brain damage. Br J Anaesth 1975;47:121–9.
[2] Slotkin TA, Cowdery TS, Orband L, Pachman S, Whitmore WL. Effects of neonatal hypoxia on brain

PM3006739452

Source: https://www.industrydocuments.ucsf.edu/docs/srnx0001

development in the rat: immediate and long-term biochemical alterations in discrete regions. Brain Res 1986;374:63–74.

[3] Glozman S, Yavin E. Lipid peroxides are generated by the fetal rat brain after episodes of global ischemia in utero. Neurochem Res 1997;22:201–8.

[4] Malamitsi-Puchner A, Economou E, Papantoniou N, Antsaklis A, Mesogitis S, Nicolopoulos D. Lipid peroxidation in healthy fetuses, preterm and full term neonates. Acta Obstet Gynecol Scan 1998;77:124–6.

[5] Vannucci RC. Experimental biology of cerebral hypoxia–ischemia: relation to perinatal brain damage. Pediatr Res 1990;27:317–26.

[6] Morikawa S, Kurauchi O, Tanaka M, Yoneda M, Uchida K, Itakura A, et al. Increased mitochondrial damage by lipid peroxidation in trophoblast cells of preeclamptic placentas. Biochem. Mol Biol Int 1997;41:767–75.

[7] Toyokuni S, Uchida K, Okamoto K, Hattori N, Hiai H, Stadtman ER. Formation of 4-hydroxy-2-nonenal-modified proteins in the renal proximal tubules of rats treated with a renal carcinogen, ferric nitrilotriacetate. Proc Natl Acad Sci U S A 1994;91:2616–20.

[8] Uchida K, Szweda LI, Chae HZ, Stadtman ER. Immunochemical detection of 4-hydroxynonenal protein adducts in oxidized hepatocytes. Proc Natl Acad Sci U S A 1993;90:8742–6.

[9] Friede RL. Pontosubicular lesions in perinatal anoxia. Arch Pathol 1972;94:343–54.

[10] Ahdab-Barmada M. Pontosubicular necrosis and hyperoxemia. Pediatrics 1980;66:840–7.

[11] Sohma O, Mito T, Mizuguchi M, Takashima S. The prenatal age critical for the development of the pontosubicular necrosis. Acta Neuropathol 1995;90:7–10.

[12] Brück Y, Brück W, Kretzschmar HA, Lassmann H. Evidence for neuronal apoptosis in pontosubicular neuron necrosis. Neuropathol Appl Neurobiol 1996;22:23–9.

[13] Scott RJ, Hegyi L. Cell death in perinatal hypoxic–ischemic brain injury. Neuropathol Appl Neurobiol 1997;22:23–9.

[14] Tan S, Zhou F, Nielsen VG, Wang Z, Galdson CL, Parks DA. Sustained hypoxia–ischemia results in reactive nitrogen and oxygen species production and injury in the premature fetal rabbit brain. J Neuropathol Exp Neurol 1998;57:544–53.

[15] Oka A, Kurachi Y, Mizuguchi M, Hayashi M, Takashima S. The expression of late infantile neuronal ceroid lipofuscinosis (CLN2) gene product in human brains. Neurosci Lett 1998;27:317–26.

[16] Ozawa H, Fukuda T, Nishida A, Takashima S. Cu, Zn-superoxide dismutase reaction in neonatal pontosubicular neuron necrosis. Pediatr Neurol 1997;16:126–30.

[17] Cafe C, Torri C, Gatti S, Adinolfi D, Gaetani P, Rodriguez Y, et al. Changes in non-synaptosomal and synaptosomal mitochondrial membrane-linked enzymatic activities after transient cerebral ischemia. Neurochem Res 1994;19:1551–5.

[18] Zanchin G, De Boni A, Lauria G, Maggioni F, Rossi P, Villacara A. Synaptosomal glutamate uptake in a model of experimental cerebral ischemia. Neurochem Res 1995;20:195–9.

[19] Keller JN, Mark RJ, Bruce AJ, Blanc E, Rothstein JD, Uchida K, et al. 4-Hydroxynonenal, an aldehydic product of membrane lipid peroxidation, impairs glutamate transport and mitochondrial function in synaptosomes. Neuroscience 1997;80:685–96.

[20] Rothstein JD, Martin L, Levey AI, Dykes-Hoberg M, Jin L, Wu D, et al. Localization of neuronal and glial glutamate transporters. Neuron 1994;13:713–25.

[21] Lehre KP, Levy LM, Ottersen OP, Storm-Mathisen J, Danbolt NC. Differential expression of two glial glutamate transporters in the rat brain: quantitative and immunocytochemical observations. J Neurosci 1995;13:713–25.

[22] Yoritaka A, Hattori N, Uchida K, Tanaka M, Stadtman ER. Immunohistochemical detection of 4-hydroxynonenal protein adducts in Parkinson disease. Proc Natl Acad Sci U S A 1996;93:2696–701.

[23] Ando Y, Nyhlin N, Suhr O, Holmgren G, Uchida K, El Sahly M, et al. Oxidative stress is found in amyloid deposits in systemic amyloidosis. Biochem Biophys Res Commun 1997;232:497–502.

[24] Ando Y, Brannstrom T, Uchida K, Nyhlin N, Nasman B, Suhr O, et al. Histochemical detection of 4-hydroxynonenal protein in Alzheimer amyloid. J Neurol Sci 1998;156:172–6.

[25] Yamashita T, Ando Y, Obayashi K, Terazaki H, Sakashita N, Uchida K, et al. Oxidative injury is present in Purkinje cells in patients with olivopontocerebellar atrophy. J Neurol Sci 2000;175:107–10.

PM3006739453

Source: https://www.industrydocuments.ucsf.edu/docs/srnx0001